

Occlusal Traits of Primary Dentition among Pre-School Children of Mehsana District, North Gujarat, India

SHOBA FERNANDES¹, DHVANI GORDHANBHAI PATEL², ERAVENI RANADHEER³, JAYASUDHA KALGUDI⁴, JAYSUKH SANTOKI⁵, SHAILA CHAUDHARY⁶

ABSTRACT

Introduction: Aesthetic and functional problems in the dentofacial complex among children are often attributed to the disturbances in the dentofacial growth and development. This can be recognized during routine dental visits. This study pursued to assess the occlusion of the primary dentition in three to five-year-old children.

Aim: To study the occlusal traits of the primary dentition in a group of three to five-year-old North Gujarat children of Mehsana district and the variation in their occlusion relative to age and gender in the same group.

Materials and Methods: The study was a cross-sectional survey based on clinical examination and photographic evaluation of the primary dentition, 383 preschool children aged three to five years who were randomly selected from preschools in Mehsana district, Gujarat, India, using a multistage sampling technique. The study group was evaluated for the several occlusal parameters that include primary molar relation based

on Baume classification and canine relation, overjet, overbite were assessed using Foster and Hamilton criteria. Chi-square test was performed to carry out statistical analysis. The p-value < 0.05 was taken as statistically significant.

Results: Out of 383 participants, 55.35% had flush terminal plane; 43.34% mesial step molar relationship and 1.31% distal step molar relationship, 63.2% had straight profile, 95.8% had Class I canine relationship, 71.3% primate spaces, 56.7% physiologic spaces. Flush terminal plane was common at three years while, mesial step at four to five years, and Class I canine relationship was prevalent in both age groups. Flush terminal plane was more common in female participants than the males. Amongst other occlusal characteristics, increased overbite and open bite were prevalent.

Conclusion: It was found that the flush terminal plane molar relationship, straight profile, Class I canine relationship, primate spacing, increased overbite and open bite predominated.

Keywords: Occlusal characteristics, Primary dentition, Occlusion, Molar relationship

INTRODUCTION

The essence of interceptive orthodontics would rely heavily on the various changes on the occlusal pattern of the primary dentition [1]. Crucial element of treatment planning includes observations of morphological changes that are dynamic, as well as occlusal patterns in the primary dentition [2]. Proper occlusion of teeth is important for many oral functions including mastication, swallowing, speech as well as respiration. Therefore, it is particularly important to have sufficient knowledge regarding the normal occlusion prevalence in primary dentition [3]. The primary dentition is accomplished with the eruption of the second primary molars, this ensures the position for eruption of the permanent teeth in the future [4]. The comprehension of the anteroposterior alterations that occur in the occlusion between the primary and permanent dentition is essential for the clinicians involved in interceptive orthodontics [5]. Bogue EA has mentioned in 1908 that if malocclusion occurred in the deciduous dentition, then corresponding permanent dentition would also experience similar irregularities, perhaps to a more pronounced degree [6]. According to Moyers RE in relation to primary dentition, generalized spacing and flush terminal plane molar relationship are rather common features observed [7]. Several observational studies concerning to the spacing and occlusion of the deciduous dentition have confirmed that the occlusal features vary among populations and ethnic groups [8]. Such data seems to be deficient in the North Gujarat population. So this study was carried out to assess the occlusal characteristic features among children of three to five year age group of Mehsana district, North Gujarat region.

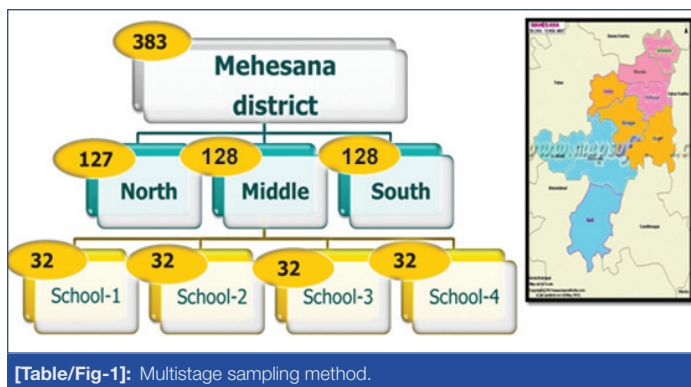
MATERIALS AND METHODS

This cross-sectional survey was based on clinical and photographic examination of the primary dentition of 383 preschool children aged three to five years from Mehsana district, Gujarat, India. (Considering the number of pre-school going children as information obtained from Mamlatdar office, Mahesana and fixing the margin of error to 5%. The sample size determined was 383.) The sample was selected randomly from total 12 schools-both private and government (Anganvadi) using a multistage sampling method. Randomization was done by chit method at every stage of sampling. The detail of the multistage sampling method is described in flow chart [Table/Fig-1]. The age of each child obtained from school records. Children with full set of primary dentition and without any partially/completely erupted permanent teeth were included in the study, while those with extensive caries, restored teeth (crowns) those with developmental anomalies were excluded from the study. The children were examined in their respective schools by a well-trained, single examiner under good day light. Using Foster and Hamilton criteria, the primary molar relation, canine relation, overjet, and overbite were assessed with the teeth in centric occlusion [9].

Molar Relationship:

Baume (1950) categorized the primary molar relationship using the distal surface of primary second molars [10].

- Flush Terminal plane: The distal surface of maxillary and mandibular primary second molars lie in the similar vertical plane.
- Mesial step: The distal surface of mandibular primary second



molar is mesial to the distal surface of maxillary primary second molar.

- (C) Distal step: The distal surface of the mandibular primary second molar is distal to the distal surface of maxillary primary second molar.

Canine Relationship:

Primary canine relationship using the following classification [9, 11]

- (A) Class I: The tip of the maxillary primary canine is in the same vertical plane as the distal surface of the mandibular primary canine.
- (B) Class II: The tip of the maxillary primary canine is mesial to the distal surface of the mandibular primary canine.
- (C) Class III: The tip of the maxillary primary canine is distal to the distal surface of the mandibular primary canine.

Assessments regarding molar relationships and canine relationship were made by assessing both sides of the dental arches. The decision was made in favour of flush terminal plane, in the case of a distal step or mesial step molar relationship on one side and flush terminal plane on the other. In case of Class II or III canine relationship on one side and Class I on other, the decision was made in favour of Class I canine relationship [9, 12, 13].

Spacing: There are two categories of spacing.

- (A) Primate spaces: The spaces mesial to the maxillary canine (pre-canine) and distal to the mandibular canine (post-canine) known as primate spaces.
- (B) Physiologic spaces: These are generalized spaces existing between primary teeth.

Other occlusal characteristics in primary dentition of selected participants were assessed, and included:

Overjet: The extent of overjet was measured from the palatal surface of the mesial corner of the most protruded fully erupted maxillary incisor to the labial surface of the corresponding mandibular incisor and was recorded in millimetres using divider and stainless steel measurement scale [9]. It was considered to be increased when it was more than 3 mm [14].

Overbite: The extent of overbite was graded according to coverage of mandibular incisor by the fully erupted maxillary incisor. Overbite was considered to be increased when the degree of overlap of the maxillary central incisors was greater than one half of the clinical crown of the mandibular central incisors, i.e., more than 3 mm and reduced if the degree of overlap was less than one-third [14].

Open bite: The degree of open bite was recorded when incisal edges of the maxillary incisors did not vertically overlap the incisal edges of the mandibular incisors.

Anterior crossbite: It was noted when one or more maxillary incisors and canines occluded lingual to the mandibular incisors.

Posterior crossbite: It was noted when one or more maxillary primary canines or molars occluded lingual to the buccal cusps of the opposing mandibular teeth.

Crowding: It was noted when there is overlapping of erupted teeth as a result of insufficient space or lack of space for teeth to erupt in a segment.

This study was carried out based on clinical examinations and photographic evaluation. Data were documented on data sheets specially designed for this study. Photographic evaluation was made using a digital camera (DSLR Canon EOS 550D). The results were tabulated and analyzed using the Statistical Package for Social Sciences (SPSS) software version-22 for windows. Chi-square test was performed to carry out statistical analysis. A p-value <0.05 was taken as statistically significant.

RESULTS

The present study assessed the occlusal traits of the primary dentition of 383 children aged, three to five years. The results are presented in [Table/Fig-2-5].

For each characteristic, comparing the proportions of mesial step and flush terminal plane molar relation, the chi-square (χ^2)

Characteristics	No. of children (n = 383)	No. of children (%)
Gender		
Male	255	66.6%
Female	128	33.4%
Profile		
Convex	135	35.2%
Straight	242	63.2%
Concave	6	1.6%
Molar relationship		
Mesial step	166	43.3%
Distal step	5	1.3%
Flush terminal plane	212	55.4%
Canine relationship		
Class I	367	95.8%
Class II	8	2.1%
Class III	8	2.1%
Primate spaces		
Present	273	71.3%
Absent	110	28.7%
Physiologic spaces		
Present	217	56.7%
Absent	166	43.3%
Increased overjet		
Present	20	5.2%
Absent	363	94.8%
Increased overbite		
Present	61	15.9%
Absent	322	84.1%
Crossbite (posterior)		
Present	6	1.6%
Absent	377	98.4%
Crowding		
Present	5	1.3%
Absent	378	98.7%
Open bite		
Present	11	2.9%
Absent	372	97.1%

[Table/Fig-2]: Prevalence of occlusal characteristics of the primary dentition in North Gujarat children of Mehsana District.

Parameters	Mesial step present (N = 166)	Mesial Step absent (N = 217)	Chi-square value	p-value
Gender				
Male	124	131	8.68	0.003
Female	42	86		
Profile				
Convex	43	92	11.20	0.004
Straight	120	122		
concave	3	3		
Canine Relationship				
Class I	156	211	2.49	0.287
Class II	5	3		
Class III	5	3		
Physiologic spaces				
Present	105	112	5.18	0.023
Absent	61	105		
Primate spaces				
Present	124	149	1.673	0.196
Absent	42	68		
Increased overjet				
Present	3	17	6.90	0.009
Absent	163	200		
Overbite				
Present	13	48	14.34	0.0009
Absent	153	169		
Crossbite				
Present	2	4	0.249	0.618
Absent	164	213		
Crowding				
Present	3	2	0.572	0.449
Absent	163	215		
Open bite				
Present	4	7	0.225	0.636
Absent	162	210		

[Table/Fig-3]: Distribution of occlusal characteristics with respect to mesial step molar relation in studied population.

test showed that the presence of mesial step and flush terminal plane molar relation was significantly ($p < 0.05$) associated with male gender, straight profile, physiological space, increased overjet and increased overbite [Table/Fig-3,4].

For each characteristic, comparing the proportions of distal step molar relation, the chi-square test showed that the presence of distal step molar relation was significantly ($p < 0.05$) associated with Class II canine relationship, crowding and openbite [Table/Fig-5].

Comparing the proportions, the chi-square test revealed no statistically significant ($p < 0.05$) association between primate spacing and any molar relations.

DISCUSSION

Normal occlusal relationships of the primary dentition are parallel those in permanent dentition. The development of malocclusion starts from the primary dentition, hence, it is very important to know the occlusion in the primary dentition, as well as the changes of occlusal pattern during the period of deciduous dentition. Transition of discrepancies from deciduous to permanent dentition has led to an increased awareness of the role of the deciduous dentition in the determination of permanent tooth position and occlusion. Thus, it is essential that conditions that influence the development of a malocclusion of the permanent dentition should be detected early

Parameters	Flush terminal Plane present (N = 212)	Flush terminal Plane absent (N = 171)	Chi-square value	p-value
Gender				
Male	127	128	9.505	0.002
Female	84	43		
Profile				
Convex	92	43	13.819	0.001
Straight	117	125		
concave	3	3		
Canine Relationship				
Class I	207	160	4.178	0.124
Class II	3	5		
Class III	2	6		
Physiologic spaces				
Present	109	108	5.315	0.021
Absent	103	63		
Primate spaces				
Present	145	128	1.928	0.165
Absent	67	43		
Increased overjet				
Present	16	4	5.187	0.023
Absent	196	167		
Overbite				
Present	48	13	15.988	0.0009
Absent	164	158		
Crossbite				
Present	4	2	0.316	0.574
Absent	208	169		
Crowding				
Present	1	4	2.562	0.149
Absent	211	167		
Open bite				
Present	6	5	0.003	0.956
Absent	206	166		

[Table/Fig-4]: Distribution of occlusal characteristics with respect to flush terminal plane molar relation in studied population.

in the primary dentition. The lack of such statistical data in North Gujarat region prompted us to undertake this study.

This study investigated the occlusal relationship and characteristics of primary dentition in the three to five-year-old children of Mehsana district. In the present study, the percentage distribution of terminal molar relationship showed flush terminal plane in 212 (55.4%) participants. The mesial step molar relationship was seen in 166 (43.3 %) participants, while distal step molar relationship was observed in 5 (1.3%) participants. Findings of several studies among children in similar age group showed predisposition for predominant flush terminal plane relationship. While the distal step was least prevalent [8,12,13,15-20].

The transition from flush terminal plane to Class I molar relationship is the ideal and commonly observed scenario. Nevertheless, mesial step was found to be the norm for completed primary dentition rather than flush terminal plane [2]. The degree of mesial step governs the progress into Angle's Class I or Class III molar relationship. In the present study, we anticipate that the majority of the sample may have a favourable permanent molar relation, as flush terminal plane was the most common molar relationship detected. However, several studies showed that the prevalence of mesial step molar relation predominates [2,21-23].

The percentage distribution of Class I canine relation was 95.8

Parameters	Distal step present (N = 5)	Distal step absent (N = 378)	Chi-square value	p-value
Gender				
Male	4	251	0.410	0.522
Female	1	127		
Profile				
Convex	0	135	2.952	0.229
Straight	5	237		
concave	0	6		
Canine Relationship				
Class I	0	367	8.019	0.018
Class II	4	4		
Class III	1	7		
Physiologic spaces				
Present	3	214	0.023	0.879
Absent	2	164		
Primate spaces				
Present	4	269	0.188	0.664
Absent	1	109		
Increased over jet				
Present	1	19	2.235	0.135
Absent	4	359		
Overbite				
Present	0	61	0.960	0.327
Absent	5	317		
Crossbite				
Present	0	6	0.081	0.776
Absent	5	372		
Crowding				
Present	1	4	13.742	0.0009
Absent	4	374		
Openbite				
Present	1	10	5.328	0.021
Absent	4	368		

[Table/Fig-5]: Distribution of occlusal characteristics with respect to distal step molar relation in studied population.

% and that of Class II canine relation was 2.1 %, Class III canine relationship was 2.1 %. These results concur with those reported by other studies [9,12,13,18-20]. However, the prevalence of Class II canine relationship (2.1%) in this sample was much lower than 42.83% in Wardha (India) [21], 45% in English children [9] and 31.6 % in Danish children [24].

In this study, percentage distribution of primate spaces was 71.3%; physiologic spacing was present in 56.7%, while no spacing was observed in 43.3%. Out of non-spaced dentition group (both physiological and primate space absent) - 60.9% participants had flush terminal plane molar relationship. The prevalence of primate and physiologic spaces was found to be greater in an English population [15], Jordanian population [22] and North and South Indian population [12, 19]. However, other Indian (Udaipur) population [12] reported lower prevalence of primate and physiologic spaces than the present study.

In other occlusal parameters, the prevalence of increased overjet was found to be 5.2% which is in accordance with other studies [8,11,12-14,20]. However, various studies found a much higher prevalence of increased overjet unlike the present study [9,24,25]. The prevalence of increased overbite in present study was found to be 15.9 %. These results concur with those reported by other Indian studies [8,12,13].

Posterior crossbite prevalence in the present study was found to be 1.6 %. Compared with the findings of other studies as in Indian (0.4%) [20], Finnish (13%) [17], Saudi Arabian (4%) [11], Nigerian (4.8%) [23] and Jordanian (7%) [22]. However, some studies found lower prevalence of posterior crossbite than the present study [12,16]. Anterior crossbite was not found in the present study compared with the findings of other studies as in Saudi population was 1.7% [11], in English population was 1.0% [9], and in South Indian population, it was 0.7% [14].

The prevalence of crowding was found to be 1.3%. However, some studies reported higher prevalence of crowding at 10% [26]. While, several other studies have found much higher prevalence 26.5%, 18.3% and 54.1% respectively, than the present study [12,13,27].

The prevalence of anterior open bite in the present study was 2.9%, in accordance with the study conducted on South Indian population [14] and other Indian study [8]. However, the study conducted on North Indian [13] and Indian population [20] found lower prevalence of openbite in primary teeth that was 0.7% and 0.2% respectively.

The present study offers insight into the state of dentition, occlusal pattern, spacing and crowding in the primary dentition among children of Mehsana district in the North Gujarat region. Presently, the results suggest a low prevalence of malocclusion in the primary dentition of this population. Further longitudinal studies are necessary to identify the probable limitations of the clinical approach relying on early orthodontic diagnosis and intervention. Further, records amassed from various parts of the country would form a valuable database.

CONCLUSION

To conclude it was observed that at three years flush terminal plane was common while, mesial step was common in four to five years age group, and Class I canine relationship was found to be prevalent in both the groups. Flush terminal plane was more common in female participants than the males. Amongst other occlusal characteristics studied, increased overbite and openbite were found to be predominant in primary dentition of North Gujarat children.

The present study provides hitherto unavailable data pertaining to the state of dentition, occlusal pattern and spacing, and crowding in the primary dentition of Indian children of North Gujarat region. Data compiled from various parts of the country, could serve as a database for prediction of malocclusion among the Indian population.

REFERENCES

- [1] Alexander S, Prabhu NT. Profiles, occlusal plane relationships and spacing of teeth in the dentitions of 3 to 4 years old children. *J Clin Pediatr Dent.* 1998;22(4):329-34.
- [2] Bishara SE, Hoppens BJ, Jakobsen JR, Kohout FJ. Changes in the molar relationship between the deciduous and permanent dentitions: A longitudinal study. *Am J Orthod Dentofacial Orthop.* 1988;93(1):19-28.
- [3] Proffit WR, Fields HW, Ackerman JL, Sinclair PM, Thomas PM, Tulloch JF. *Early Stages of Development. Contemporary Orthodontics.* 4th ed. St. Louis: Mosby-Year Book; 1993. Pp. 72-106
- [4] Nakata M, Wei S. *Occlusal guidance in pediatric dentistry.* Saint Louis, Missouri: Ishiyaku Euro America Inc; 1988. pp. 12-3.
- [5] Malandris M, Mahoney EK. Aetiology, diagnosis and treatment of posterior cross-bites in the primary dentition. *Int J Paediat Dent.* 2004;14(3):155-66.
- [6] Bogue EA. Some results from orthodontia on deciduous teeth. *Am Med Assoc.* 1908;1:267-69.
- [7] Moyers RE. *Handbook of Orthodontics,* 3rd edn. Chicago: Yearbook Medical Publishers;1972.
- [8] Vegesna M, Chandrasekhar R, Chandrappa V. Occlusal characteristics and spacing in primary dentition: A gender comparative cross-sectional study. *Int Sch Res Notices.* 2014;2014:512680.
- [9] Foster TD, Hamilton MC. Occlusion in the primary dentition. Study of children at 2.5 to 3 years age. *Br Dent J.* 1969;126(2):76-79.
- [10] Baume LJ. Physiological tooth migration and its significance for the development of occlusion: I. The biogenetic course of deciduous dentition. *J Dent Res.* 1950;29:123-32.
- [11] Farsi NM, Salama FS. Characteristics of primary dentition occlusion in a group of Saudi children. *Int J Paediat Dent.* 1996;6(4):253-59.
- [12] Hegde S, Panwar S, Bolar DR, Sanghavi MB. Characteristics of occlusion in

- primary dentition of preschool children of Udaipur, India. *Eur J Dent.* 2012;6(1):51–55.
- [13] Khan R, Singh N, Govil S, Tandon S. Occlusion and occlusal characteristics of primary dentition in North Indian children of East Lucknow region. *Eur Arch Paediatr Dent.* 2014;15:293–99.
- [14] Reddy BP, Rani MS, Santosh R, Shailaja AM. Incidence of malocclusion in deciduous dentition of Bangalore South population- India. *IJCD.* 2010;1(1):20–23.
- [15] Bokyo DJ. The incidence of primate spaces in fifty; 3 year old children of the urlington Study. *Am J Orthod.* 1968;54(6):462–65.
- [16] Kaufman A, Koyoumdjisky E. Normal occlusal patterns in the deciduous dentition in preschool children in Israel. *J Dent Res.* 1967;46(3):478–82.
- [17] Kerosuo H, Laine T, Nyssonen V, Honkala E. Occlusal characteristics in groups of Tanzanian and Finnish urban school children. *Angle Orthod.* 1991;61(1):49–56.
- [18] Nanda RS, Khan I, Anand R. Age changes in the occlusal pattern of deciduous dentition. *J Dent Res.* 1973;52(2):221–24.
- [19] Shavi GR, Hiremath NV, Shukla R, Bali PK, Jain SK, Ajagannanavar SL. Prevalence of spaced and non-spaced dentition and occlusal relationship of primary dentition and its relation to malocclusion in school children of Davangere. *J Int Oral Health.* 2015;7(9):75–78.
- [20] Bhat SS, Rao HA, Hegde KS, Kumar BK. Characteristics of primary dentitionocclusion in preschool children: An epidemiological study. *Int J Clin Pediatr Dent.* 2012;5(2):93–97.
- [21] Bahadure RN, Thosar N, Gaikwad R. Occlusal traits of deciduous dentition of preschool children of Indian children. *Contemp Clin Dent.* 2012;3(4):443–47.
- [22] Abu Alhaija ES, Qudeimat MA. Occlusion and tooth/arch dimensions in the primary dentition of preschool Jordanian children. *Int J Paediatr Dent.* 2003;13(4):230–39.
- [23] Otuyemi OD, Sote EO, Isiekwe MC, Jones SP. Occlusal relationships and spacing or crowding of teeth in the dentitions of 3–4-year old Nigerian children. *Int J Paediatr Dent.* 1997;7(3):155–60.
- [24] Ravn JJ. Occlusion in the primary dentition in 3-year-old children. *Scand J Dent Res.* 1975;83(3):123–30.
- [25] Infante PF. An epidemologic study of deciduous molar relations in preschool children. *J Dent Res.* 1975;54(4):723–27
- [26] Suma G, Das UM. Crowding, spacing and closed dentition and its relationship with malocclusion in primary dentition. *Int J Clin Dent Sci.* 2010;1(1):16–19.
- [27] Tschill P, Bacon W, Sonko A. Malocclusion in the deciduous dentition of Caucasian children. *Eur J Orthod.* 1997;19(4):361–67.

PARTICULARS OF CONTRIBUTORS:

1. Professor and Head, Department of Paediatric and Preventive Dentistry, Narsinhbhai Patel Dental College, Visnagar, Gujarat, India.
2. Postgraduate, Department of Paediatric and Preventive Dentistry, Narsinhbhai Patel Dental College, Visnagar, Gujarat, India.
3. Professor, Department of Paediatric and Preventive Dentistry, Narsinhbhai Patel Dental College, Visnagar, Gujarat, India.
4. Professor, Department of Paediatric and Preventive Dentistry, Narsinhbhai Patel Dental College, Visnagar, Gujarat, India.
5. Postgraduate, Department of Paediatric and Preventive Dentistry, Narsinhbhai Patel Dental College, Visnagar, Gujarat, India.
6. Postgraduate, Department of Paediatric and Preventive Dentistry, Narsinhbhai Patel Dental College, Visnagar, Gujarat, India.

NAME, ADDRESS, E-MAIL ID OF THE CORRESPONDING AUTHOR:

Dr. Shoba Fernandes,
 Professor and Head, Department of Paediatric and Preventive Dentistry, Narsinhbhai Patel Dental College, Visnagar-384315,
 Gujarat, India.
 E-mail: vshobaf@gmail.com

Date of Submission: **Jul 14, 2016**
 Date of Peer Review: **Sep 15, 2016**
 Date of Acceptance: **Oct 21, 2016**
 Date of Publishing: **Jan 01, 2017**

FINANCIAL OR OTHER COMPETING INTERESTS: None.